


Leptospirosis

PAUL N. LEVETT*

I , *S* *C* *M* & *R* , *L* *L* ,
M *H* , *B*



nosis of leptospirosis by serological and molecular methods are analyzed.



Leptospirosis is a zoonosis of ubiquitous distribution, caused by infection with pathogenic *L* species. The spectrum of human disease caused by leptospire is extremely wide, ranging from subclinical infection to a severe syndrome of multiorgan infection with high mortality. This syndrome, icteric leptospirosis with renal failure, was first reported over 100 years ago by Adolf Weil in Heidelberg (624). However, an apparently identical syndrome occurring in sewer workers was described several years earlier (337, 338). Earlier descriptions of diseases that were probably leptospirosis were reviewed recently (207, 211). Leptospirosis was certainly recognized as an occupational hazard of rice harvesting in ancient China (211), and the Japanese name akiyami, or autumn fever, persists in modern medicine. With hindsight, clear descriptions of leptospiral jaundice can be recognized as having appeared earlier in the 19th century, some years before the description by Weil (211). It has been suggested that *L* serovar icterohaemorrhagiae was introduced to western Europe in the 18th century by westward extension of the range of of *R* from Eurasia (24).

The etiology of leptospirosis was demonstrated independently in 1915 in Japan and Germany (207). In Japan, Inada and Ido detected both spirochetes and specific antibodies in the blood estwa0(Japah)-402ttwa0(Japahm-1.2285 I1a)-402..2285 I1ca46ion u ItIt

TABLE 2. Genomospecies of *L.* and distribution of serogroups

Species	Serogroups
<i>L. interrogans</i>	Icterohaemorrhagiae, Canicola, Pomona, Australis, Autumnalis, Pyrogenes, Grippityphosa, Djasiman, Hebdomadis, Sejroe, Bataviae, Ranarum, Louisiana, Mini, Sarmin
<i>L. interrogans</i>	Panama, Autumnalis, Pyrogenes, Louisiana, Bataviae, Tarassovi, Australis, Shermani, Djasiman, Pomona
<i>L. interrogans</i>	Shermani, Hebdomadis, Tarassovi, Pyrogenes, Autumnalis, Bataviae, Mini, Grippityphosa, Sejroe, Pomona, Javanica, Sarmin, Cynopteri
<i>L. interrogans</i>	Ranarum, Semarang, Sejroe, Mini, Javanica
<i>L. interrogans</i>	Codice
<i>L. interrogans</i>	Semarang, Andamana
<i>L. interrogans</i>	Hurstbridge
<i>L. interrogans</i>	Javanica, Ballum, Hebdomadis, Sejroe, Tarassovi, Mini, Celledoni, Pyrogenes, Bataviae, Australis, Autumnalis
<i>L. interrogans</i>	Grippityphosa, Autumnalis, Cynopteri, Hebdomadis, Australis, Pomona, Djasiman, Canicola, Icterohaemorrhagiae, Bataviae,
<i>L. interrogans</i>	Celledoni, Icterohaemorrhagiae, Sarmin, Javanica, Mini, Tarassovi, Hebdomadis, Pyrogenes, Manhao, Sejroe
<i>L. interrogans</i>	Lyme, Shermani, Icterohaemorrhagiae, Tarassovi, Manhao, Canicola, Panama, Javanica

L. interrogans serogroups: I T 3 T S , -33 . A . . T

ies led to the definition of 10 genomospecies of *L.* (658). An additional genomospecies, *L.* , was added later (475). After an extensive study of several hundred strains, workers at the Centers for Disease Control (CDC) more recently defined 16 genomospecies of *L.* that included those described previously (475, 658) and adding five new genomospecies (81), one of which was named *L.* . An additional species, *L.* , has since been described, which contains a new serovar, hurstbridge (450). DNA hybridization studies have also confirmed the taxonomic status of the monospecific genus *L.* (81, 474). The genotypic classification of leptospire is supported by multilocus enzyme electrophoresis data (348), but recent studies suggest that further taxonomic revisions are likely (348, 462).

The genomospecies of *L.* do not correspond to the previous two species (*L.* and *L.*), and indeed, pathogenic and nonpathogenic serovars occur within the same species (Table 2). Thus, neither serogroup nor serovar reliably predicts the species of *L.* (Table 3). Moreover, recent studies (81, 222) have included multiple strains of some serovars and demonstrated genetic heterogeneity within serovars (Table 4). In addition, the phenotypic characteristics formerly

used to differentiate *L.* sensu lato from *L.* sensu lato do not differentiate the genomospecies (81, 658). The reclassification of leptospire on genotypic grounds is taxonomically correct and provides a strong foundation for




FIG. 1. Scanning electron micrograph of *L. interrogans* serovar *icterohaemorrhagiae* strain RGA bound to a 0.2- μ m membrane filter. Reproduced from reference 625a with permission from the publisher.

future classifications. However, the molecular classification is problematic for the clinical microbiologist, because it is clearly incompatible with the system of serogroups which has served clinicians and epidemiologists well for many years. Until simpler DNA-based identification methods are developed and validated, it will be necessary for clinical laboratories to retain the serological classification of pathogenic leptospires for the foreseeable future. In addition, the retention of *L.*

and *L.* as specific names in the genomic classification also allows nomenclatural confusion. In the following pages, specific names refer to the genomospecies, including *L.* sensu stricto and *L.* sensu stricto.

Leptospires are tightly coiled spirochetes, usually 0.1 μ m by 6 to 0.1 by 20 μ m, but occasional cultures may contain much longer cells. The helical amplitude is approximately 0.1 to 0.15 μ m, and the wavelength is approximately 0.5 μ m (213). The cells have pointed ends, either or both of which are usually bent into a distinctive hook (Fig. 1). Two axial filaments (periplasmic flagella) with polar insertions are located in the periplasmic space (550). The structure of the flagellar proteins is complex (583). Leptospires exhibit two distinct forms of movement, translational and nontranslational (60). Morphologically all leptospires are indistinguishable, but the morphology of individual isolates varies with subculture in vitro and can be restored by passage in hamsters (186). Leptospires have a typical double membrane structure in common with other spirochetes, in which the cytoplasmic membrane and peptidoglycan cell wall are closely associated and are overlain by an outer membrane (254). Leptospiral lipopolysaccharide has a composition similar to that of other gram-negative bacteria (603), but has lower endotoxic activity (519). Leptospires may be stained using carbol fuchsin counterstain (211).

Leptospires are obligate aerobes with an optimum growth temperature of 28 to 30°C. They produce both catalase and oxidase (530). They grow in simple media enriched with vitamins (vitamins B₂ and B₁₂ are growth factors), long-chain fatty acids, and ammonium salts (309). Long-chain fatty acids are utilized as the sole carbon source and are metabolized by β -oxidation (530).

Growth of leptospires in media containing either serum or albumin plus polysorbate and in protein-free synthetic media has been described (587). Several liquid media containing rabbit serum were described by Fletcher, Korthoff, Noguchi, and Stuart (587); recipes for these earlier media are found in several monographs (24, 213, 548, 634). The most widely used medium in current practice is based on the oleic acid-albumin medium EMJH (184, 310). This medium is available commercially from several manufacturers and contains Tween 80 and bovine serum albumin. Some strains are more fastidious and require the addition of either pyruvate (312) or rabbit serum (196) for initial isolation. Growth of contaminants from clinical specimens can be inhibited by the addition of 5-fluorouracil (311). Other antibiotics have been added to media for culture of veterinary specimens, in which contamination is more likely to occur (8, 413). Protein-free media have been developed for use in vaccine production (64, 504, 518, 541).

Growth of leptospires is often slow on primary isolation, and cultures are retained for up to 13 weeks before being discarded, but pure subcultures in liquid media usually grow within 10 to 14 days. Agar may be added at low concentrations (0.1 to 0.2%). In semisolid media, growth reaches a maximum density in a discrete zone beneath the surface of the medium, which becomes increasingly turbid as incubation proceeds. This growth is related to the optimum oxygen tension (213) and is known as a Dinger's ring or disk (164). Leptospiral cultures may be maintained by repeated subculture (608) or preferably by storage in semisolid agar containing hemoglobin (213). Long-term storage by lyophilization (31) or at -70°C (20, 432) is also used.

Growth on media solidified with agar has been reported (494, 587). Colonial morphology is dependent on agar concentration and serovar (582). Media can also be solidified using gellan gum (496). Solid media have been used for isolation of leptospires (572), to separate mixed cultures of leptospires, and for detection of hemolysin production (539).

Leptospires are phylogenetically related to other spirochetes (446). The leptospiral genome is approximately 5,000 kb in size (52, 669), although smaller estimates have been reported (558, 649). The genome is comprised of two sections, a 4,400-kb chromosome and a smaller 350-kb chromosome (669). Other plasmids have not been reported (125, 292). Physical maps have been constructed from serovars *pomona* subtype *kennewicki* (669) and *icterohaemorrhagiae* (74, 552). Leptospires contain two sets of 16S and 23S rRNA genes but only one 5S rRNA gene (230), and the rRNA genes are widely spaced (51, 231).

The study of leptospiral genetics has been slowed by the lack

tenance hosts of serovar hardjo (192), and infection with this serovar occurs throughout the world (45, 412, 466). Many animals are seronegative carriers (192, 267, 571). After infection, leptospires localize in the kidneys (249, 427, 465, 571, 626) and are excreted intermittently in the urine (189). Serovar hardjo causes outbreaks of mastitis (196) and abortion (190). Serovar hardjo is found in aborted fetuses and in premature calves (188, 194, 238, 268). In addition, hardjo has been isolated from normal fetuses (191), the genital tracts of pregnant cattle (191), vaginal discharge after calving (193), and the gen-

ease represents only the most severe presentation. Formerly it was considered that distinct clinical syndromes were associated with specific serogroups (596). However, this view was questioned by some authorities (18, 180, 220), and more intense study over the past 30 years has refuted this hypothesis. An explanation for many of the observed associations may be found in the ecology of the maintenance animal hosts in a geographic region. A region with a richly varied fauna will support a greater variety of serogroups than will a region with few animal hosts. In humans, severe leptospirosis is frequently but not invariably caused by serovars of the icterohaemorrhagiae serogroup. The specific serovars involved depend largely on the geographic location and the ecology of local maintenance hosts. Thus in Europe, serovars *copenhageni* and *icterohaemorrhagiae*, carried by rats, are usually responsible for infectious, while in Southeast Asia, serovar *lai* is common.

The clinical presentation of leptospirosis is biphasic (Fig. 2), with the acute or septicemic phase lasting about a week, followed by the immune phase, characterized by antibody production and excretion of leptospire in the urine (180, 325, 585). Most of the complications of leptospirosis are associated with localization of leptospire within the tissues during the

tic meningitis have tended to be younger than those with icteric leptospirosis (57, 328, 522). In their series of 616 cases, Alston and Broom (24) noted that 62% of children ≤ 14 years old presented with aseptic meningitis, whereas only 31% of patients aged 15 to 29 years did so and only 10% of those over 30 years of age. Mortality is almost nil in anicteric leptospirosis (180), but death resulting from massive pulmonary hemorrhage occurred in 2.4% of the anicteric patients in a Chinese outbreak (615).

The differential diagnosis must include common viral infections, such as influenza (18), human immunodeficiency virus seroconversion (290), and, in the tropics, dengue (332, 350, 501), in addition to the bacterial causes of fever of unknown origin, such as typhoid. Turner (585) provided a comprehensive list of other conditions that may be mimicked by leptospirosis, including encephalitis, poliomyelitis, rickettsiosis, glandular fever (infectious mononucleosis), brucellosis, malaria, viral hepatitis, and pneumonitis. Hantavirus infections must also be considered in the differential diagnosis for patients with pulmonary involvement (32). Petechial or purpuric lesions may occur (49g (49g2rs, viral hemorrhagic fevers have been reported turning from Africa (278, 402).

Icteric rs, st a much more severe disease in which the clinical course st often very rapidly prog-3-sive. Severe 48Coften present late in the course of the disease, ,g contributostthe high mortality rate, which range4stbetween5 and 15%. Between5and 10% ule6t67.3(alle6t67.3 (patients)-267.3(with)-267.3(leptospirosis)]TJT*[(have)-279.3(the)-279.3(icteric)-279.3(for) tost72sthst(417). In patients with ARF, oliguriast(odds ratio [OR], 9.9849 was a significant predictor of death (142).

Serum amylase levels are often raised significantly in association with ARF (49g75g22), but clinical sym, of pancreatitis are not a common finding (174, 401, 439). Necrotizing pancreatitis has been detected at autopsy (175g44). Thrombocytopeniast(plateletstcountstof 100×10

in $\geq 50\%$ of 48Cis a significant predictor for the development of ARF (176). However, thrombocytopeniast369(in)-369(rs)-4iecast st transient and doe not result from disseminated intravascular coagulation (179, 419).

The occurrence of pulmonary sym, in 48Cof rs, 4iecastwatfirstnotedbySilverstein (525). Subsequent reports in travelers re- have shown that pulmonary involvement may be the major manifestation of rs, in some clustert of 48C(294, 510, 614in66440, sporadic 48C(63, 461). The severity ule6449.8(respiratory)-449.8(disease)-449.8(is)-449.8(unrelated)-

9/liter49occurs

in a series of jaundiced patients in Brazil, only 17% had clinical evidence of pulmonary involvement, but 33% had radiographic abnormalities (415). In a large Chinese series, moist rales were noted in 17% of cases (115). Rales are more common in icteric than in nonicteric leptospirosis (18). Concurrent hemoptysis and pulmonary infiltrates on chest radiographs were noted in 12% of 69 nonfatal cases in the Seychelles (659). Cigarette smoking was reported as a risk factor for the development of pulmonary symptoms (375).

Radiography generally reveals diffuse small opacities which may be widely disseminated or which may coalesce into larger areas of consolidation, with increasing severity of symptoms (342, 415, 525, 614, 659, 664). Pleural effusions may occur (342, 560). The patchy infiltrates which are commonly seen reflect areas of intra-alveolar and interstitial hemorrhage (294, 419, 472, 614, 664). Both alveolar infiltrates (OR 7.3) and dyspnea (OR 11.7) are poor prognostic indicators in severe leptospirosis (172). Similarly, in icteric leptospirosis in Brazil, respiratory insufficiency (OR 4.6) was associated with death (332).

Cardiac involvement in leptospirosis is common but may be underestimated. Fatal myocarditis was first described in 1935 (400). Clinical evidence of myocardial involvement, including abnormal T waves, was detected in 10% of 80 severe icteric cases in Louisiana (536), while similar electrocardiographic (ECG) abnormalities were detected in over 40% of patients in China, India, Sri Lanka, and the Philippines (353, 467, 471, 618), including both icteric and nonicteric cases. However, in a prospective study in Malaysia, identical ECG changes were found in patients with either leptospirosis or malaria (445), and it was concluded that such ECG changes were nonspecific. Other ECG abnormalities have been reported less frequently (470). The presence of myocarditis was strongly associated with the severity of pulmonary symptoms in anicteric Chinese patients (353). A mortality rate of 54% was reported in severe leptospirosis cases with myocarditis (341). Repolarization abnormalities on ECG were considered a poor prognostic indicator (OR 5.9) in severe leptospirosis cases (172), as were arrhythmias (OR 2.83) in a Brazilian series (332).

Ocular manifestations of severe leptospirosis were noted in early reports (622, 624). Conjunctival suffusion is seen in the majority of patients in some series (377). Conjunctival suffusion in the presence of scleral icterus is said to be pathognomonic of Weil's disease (596). Anterior uveitis, either unilateral or bilateral, occurs after recovery from the acute illness in a minority of cases (53). Uveitis may present weeks, months, or occasionally years after the acute stage. Chronic visual disturbance, persisting 20 years or more after the acute illness, has been reported (521).

The incidence of ocular complications is variable, but this probably reflects the long time scale over which they may occur. In the United States the incidence was estimated at 3% (273), while in Romania an incidence of 2% was estimated between 1979 and 1985 (28). However, in abattoir workers with evidence of recent leptospirosis, the latter authors reported an incidence of 40% (28).

In most cases uveitis is presumed to be an immune phenomenon, but leptospirae have been isolated from human and

equine eyes (16, 209), and more recently, leptospiral DNA has been demonstrated in aqueous humor by PCR (114, 209, 389). Late-onset uveitis may result from an autoimmune reaction to subsequent exposure (211).

Recently, a large cluster of cases of uveitis was reported from Madurai in southern India following an outbreak of leptospirosis which occurred after heavy flooding (114, 477, 478). The majority of affected patients were males, with a mean age of 35 years (477). Eyes were involved bilaterally in 38 patients (52%), and panuveitis was present in 96% of eyes. Other significant ocular findings included anterior chamber cells, vitreous opacities, and vasculitis in the absence of visual deficit (114).

Acute infection in pregnancy has been reported to cause abortion (116) and fetal death (122, 214), but not invariably so. In one of the cases reported by Chung et al. (116), leptospirae were isolated from amniotic fluid, placenta, and cord blood; the infant was mildly ill and was discharged at 2 weeks of age. In another case, a neonate developed jaundice and died 2 days after birth (356). Leptospirae were demonstrated in the liver and kidneys by silver staining, but serological evidence of leptospiral infection in the mother was only obtained 2 weeks after delivery. Leptospirae have been isolated from human breast milk (116), and in one case serovar hardjo was probably transmitted from an infected mother to her infant by breastfeeding (70).

Rare complications include cerebrovascular accidents (224, 346), rhabdomyolysis (133, 374, 537), thrombotic thrombocytopenic purpura (336), acute acalculous cholecystitis (44, 401, 600), erythema nodosum (157), aortic stenosis (91), Kawasaki syndrome (291, 636), reactive arthritis (633), epididymitis (285), nerve palsy (516, 578), male hypogonadism (437), and Guillain-Barré syndrome (403). Cerebral arteritis, resembling Moyamoya disease, has been reported in a series of patients from China (650).

Anecdotal reports suggest that leptospirosis may induce chronic symptoms analogous to those produced by other spirochetal infections, such as Lyme disease. However, there is very little objective evidence to support or disprove this hypothesis. The possibility of chronic human infection was suggested, without evidence of infection other than serology (420). A single case of late-onset meningitis following icteric leptospirosis has been described (406), in which leptospirae were isolated from both cerebrospinal fluid (CSF) and urine. This patient exhibited a negligible antibody response to the infecting strain, suggesting the presence of an immune defect.

Of the sequelae of acute leptospirosis described above, uveitis is a potentially chronic condition and is a recognized chronic sequel of leptospirosis in humans and horses. Equine recurrent uveitis appears to be an autoimmune disease (358, 443), and Faine (211) suggested that late-onset uveitis in humans may result from an autoimmune reaction to subsequent exposure. Immune involvement in retinal pathology has been demonstrated in horses with spontaneous uveitis (318). Leptospirae have been isolated from the human eye (16), and more

recently, leptospiral DNA has been amplified from aqueous humor (114, 367, 389) of patients with uveitis. In these cases, uveitis has occurred relatively soon after the acute illness.

One follow-up study of 11 patients with a mean time of 22 years (range, 6 to 34 years) after recovery from acute leptospirosis has been reported (521). Four patients complained of persistent headaches since their acute illness. Two patients complained of visual disturbances; both had evidence of past bilateral anterior uveitis. No biochemical or hematologic abnormalities were detected to suggest continuing liver or renal impairment. No studies to date have attempted to confirm the persistence of leptospire in the tissues of patients who have subsequently died of other causes.

Leptospirosis is characterized by the development of vasculitis, endothelial damage, and inflammatory infiltrates composed of monocyte cells, plasma cells, histiocytes, and neutrophils. On gross examination, petechial hemorrhages are common and may be extensive (35), and organs are often discolored due to the degree of icterus (459). The histopathology is most marked in the liver, kidneys, heart, and lungs (665), but other organs may

disease caused by the homologous serovar or antigenically similar serovars only. Vaccines must therefore contain serovars representative of those present in the population to be immunized. Immunization has been widely used for many years as a means of inducing immunity in animals and humans, with limited success. Early vaccines were composed of suspensions of killed leptospire cultures in serum-containing medium, and side effects were common. Modern vaccines prepared using protein-free medium are generally without such adverse effects (64, 113). In developed countries, pigs and cattle are widely immunized, as are domestic dogs, but in most developing countries, vaccines which contain the locally relevant serovars are not available. Most vaccines require booster doses at yearly intervals.

Most bovine and porcine vaccines contain serovars hardjo and pomona; in North America, commercial vaccines also contain serovars canicola, grippityphosa, and icterohaemorrhagiae. Protection against hardjo infection has been suboptimal, but one vaccine has recently been shown to offer good protection (C. A. Bolin, D. P. Alt, and R. L. Zuerner, Abstr. 2nd Int. Leptospirosis Soc. Meet., 1999. abstr. 18) and induces a cell-mediated immune response.

Canine vaccines generally contain serovars canicola and icterohaemorrhagiae. Vaccines protect against disease and renal shedding under experimental conditions (82), but transmission of serovar icterohaemorrhagiae from immunized dogs to humans has been reported (221). Moreover, immunized dogs may be infected with serovars other than those contained in commercial vaccines (83, 123, 206, 261, 464). A vaccine has been released recently which includes serovars grippityphosa and pomona in addition to the traditional vaccine strains, in response to the increasing incidence of canine infection with these serovars.

leptospirosis and septicemia, such antibodies are directed against cryptantigens exposed on damaged platelets and do not play a causal role in the development of thrombocytopenia (592). Other autoantibodies have been detected in acute illness, including IgG anticardiolipin antibodies (495) and antineutrophil cytoplasmic antibodies (127). However, the significance of antineutrophil cytoplasmic antibodies in the pathogenesis of vascular injury in leptospirosis has been questioned (1).

Virulent leptospire induce apoptosis in vivo and in vitro (388, 391). In mice, apoptosis of lymphocytes is elicited by LPS via induction of tumor necrosis factor alpha (TNF- α) (299). Elevated levels of inflammatory cytokines such as TNF- α have been reported in patients with leptospirosis (203).



The outer membrane of leptospire contains LPS and several lipoproteins (outer membrane proteins [OMPs]) (254). The LPS is highly immunogenic and is responsible for serovar specificity (107, 152). An inverse relationship between expression of transmembrane OMPs and virulence was demonstrated in serovar grippityphosa (259). Outer membrane lipoprotein LipL36 is downregulated in vivo (56) and is not recognized by the humoral immune response to host-adapted leptospirosis in hamsters (257). Other OMPs are also downregulated in vivo (418). Outer membrane components may be important in the pathogenesis of interstitial nephritis (56, 256). A fibronectin-binding protein produced only by virulent strains was described recently (390).



Immunity to leptospirosis is largely humoral in nature (7). Passive immunity can be conferred by antibodies alone (6, 316, 505). A serovar-specific antigen (F4) extracted from LPS (215) lacked endotoxic activity and induced protective immunity in rabbits, guinea pigs, and mice (216). A similar antigen (TM), which inhibited agglutination by homologous antisera (3), was shown to be distinct from F4 (10) but had a common epitope (12). Sodium dodecyl sulfate extracts of whole cells induced production of protective antibody, which was also agglutinating and complement fixing

o803ibrssh154T*(sh1sh154T*tkyv4.o)-372.1i-adaps a.1i-ad g.1i-ado5(g.1i-adclos9.4(h.1i-adnshipped(a.1i-ad)-371.5s. pathnumb322(m66ipo-6r8.66ipoCD4/F9 1 6f-10.7 0 0 5.5 -2..52 10si75 Tm(1/F7 1 Tf-10.9 0 0 Tf(ep65 -03 Tmckeyma)-cyt5s5..66ipo-367.4(6i

634). Direct dark-field microscopy of blood is also subject to misinterpretation of fibrin or protein threads, which may show Brownian motion (213, 587, 634).

Staining methods have been applied to increase the sensitivity of direct microscopic examination. These have included immunofluorescence staining of bovine urine (72, 284), water, and soil (275) and immunoperoxidase staining of blood and urine (562). A variety of histopathological stains have been

tospiral serovars. After incubation, the serum-antigen mixtures are examined microscopically for agglutination, and the titers are determined. Formerly, the method was known as the agglutination-lysis test because of the formation of lysis balls (506) or lysis globules (596) of cellular debris in the presence of high-titered antiserum. However, these are tightly agglutinated clumps of leptospire containing live cells and not debris (586).

Several modifications of earlier methods (124, 235, 549, 634) led to an MAT method which can be performed and read in microtiter trays. Protocols for performing the MAT have been described in detail (17, 210, 322, 548). The MAT is a complex test to control, perform, and interpret (586). Live cultures of all serovars required for use as antigens must be maintained. This applies equally whether the test is performed with live or formalin-killed antigens. The repeated weekly subculture of large numbers of strains presents hazards for laboratory workers, and laboratory-acquired infections have been reported (16, 460). Other drawbacks include the continuous risk of cross-contamination of the antigen cultures, necessitating periodic verification of each serovar. MAT titers are affected by the culture medium in which the antigens are grown (409).

The range of antigens used should include serovars representative of all serogroups (210, 586) and all locally common serovars (579). Antibody titers to local isolates are often higher than titers to laboratory stock strains of serovars within the same serogroup. It is usual to include one of the serovars of the nonpathogenic species *L. interrogans* (276, 557). Such a wide range of antigens is used in order to detect infections with uncommon or previously undetected serovars (320). Contrary to a widely held belief, the MAT is a serogroup-specific assay. In many reports which purport to show serovar specificity, a limited range of serogroups were tested, each represented by only a single serovar. Moreover, few studies have attempted to correlate the presumptive serogroup determined by MAT with the results of culture. However, the ability of convalescent-phase MAT titers to predict even the infecting serogroup may be as low as 40% (P. N. Levett, Abstr. 2nd Int. Leptospirosis

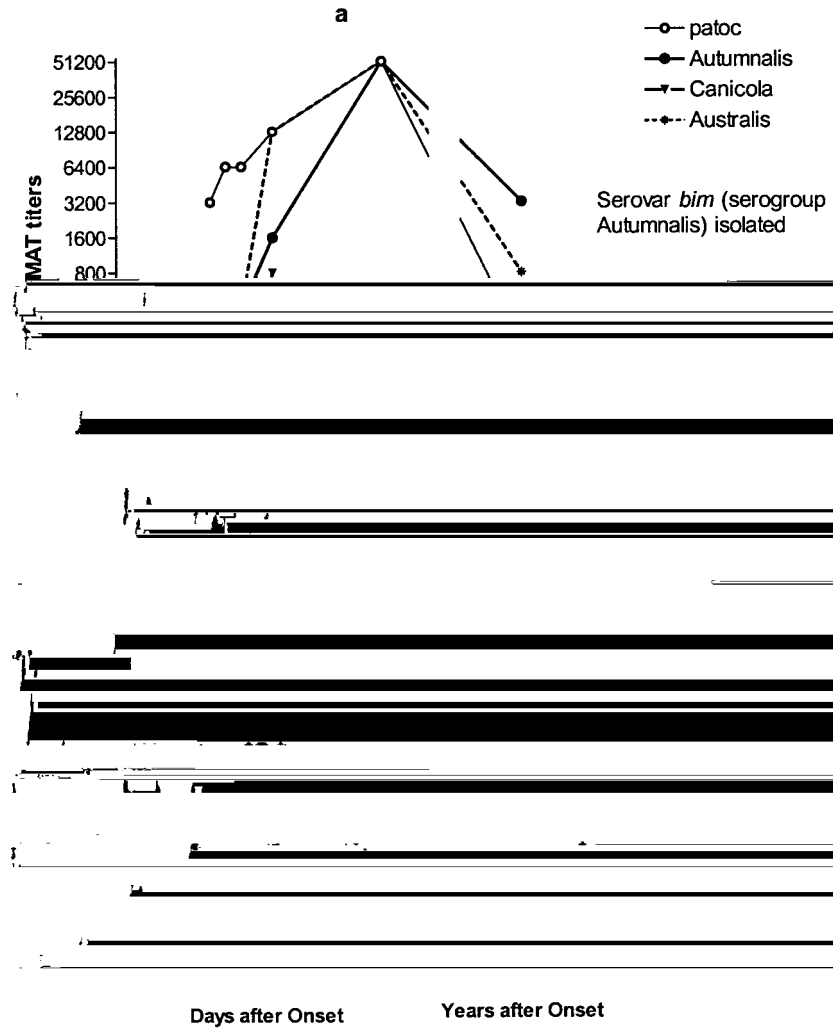


FIG. 3. Paradoxical immune response to acute infection with serovar bim, in which the presumptive serogroup (Autumnalis) was identified during follow-up (a), and copenhageni, in which serogroup Icterohaemorrhagiae was never identified as the predominant serogroup (b).

expanded or decreased as required. It is usual to use a titer of ≥ 100 as evidence of past exposure (210). However, conclusions about infecting serovars cannot be drawn without isolates; at best, the MAT data can give a general impression about which serogroups are present within a population.

Because of the complexity of the MAT, rapid screening tests for leptospiral antibodies in acute infection have been developed (Table 8). Complement fixation (CF) was widely used (24, 586, 595, 634), but methods were not standardized. CF was applied to veterinary diagnosis, but species-specific differences were noted (488). CF tests have generally been replaced by ELISA methods (11, 365, 440, 565, 566). IgM antibodies become detectable during the first week of illness (11, 112, 173, 351, 617), allowing the diagnosis to be confirmed and treatment initiated while it is likely to be most effective. IgM detection has repeatedly been shown to be more

sensitive than MAT when the first specimen is taken early in the acute phase of the illness (140, 484, 632).

IgM antibodies have been detected by ELISA in CSF from patients with icteric leptospirosis (94). In patients with meningitis without a proven etiology, IgM was detected in the CSF in 15% (522). IgM has been detected in saliva (524), and a dot-ELISA using polyester fiber was developed to facilitate collection of saliva directly onto the support material (523).

ELISA methods have been applied in a number of modifications. An IgM-specific dot-ELISA was developed in which polyvalent leptospiral antigen was dotted onto nitrocellulose filter disks in microtiter tray wells, allowing the use of smaller volumes of reagents. Further modifications of this approach have been used to detect IgG and IgA in addition to IgM (524) and have employed an immunodominant antigen (485) and a polyester fabric-resin support in place of nitrocellulose (523).

A commercial IgM dot-ELISA dipstick has been shown to be as sensitive as a microtiter plate IgM-ELISA (350a). Another dipstick assay (253) has been extensively evaluated in several populations (512, 533, 661). A dot immunoblot assay using colloidal gold conjugate allowed completion of the assay within 30 min (455).

In contrast to the applications of ELISA for diagnosis of human infection, in which broadly reactive assays are generally desirable and few serovar-specific assays have been developed (395), veterinary applications have been directed towards detection of serovar-specific antibodies, particularly for detection of infection in food animals. ELISA methods have been described for detection of serovar pomona (134, 573) and hardjo (5, 58, 573, 653) infection in cattle and hardjo in sheep (9). Several assays are available commercially for serodiagnosis of bovine hardjo infection and have been evaluated (642). IgM detection by ELISA has also been applied to canine diagnosis (264, 265, 623).

A macroscopic slide agglutination test was described in which 12 serovars were combined into four pools for the rapid screening of sera from humans and animals (234). Despite the use of an expanded antigen range, false-negative results were reported for sera from populations in areas of endemic leptospirosis (635). Several modifications of this test have used a single serovar antigen, usually serovar patoc (76, 364, 369, 621). Some studies have reported that the patoc slide test is insensitive (369, 546, 616), but a commercial slide agglutination assay was recently found to be as sensitive and specific as an IgM-ELISA while remaining reactive for a shorter time after recovery than either the IgM-ELISA or the MAT (77).

A number of methods using sensitized red blood cells have been described. The extraction of an erythrocyte-sensitizing substance led to the development of both a hemolytic assay requiring complement (135, 136) and a hemagglutination assay (383, 547), and a number of modifications of the latter have been described (295, 499). These assays detect both IgM and IgG antibodies (351, 431). The indirect hemagglutination assay (IHA) developed at CDC (547) was shown to have a sensitivity of 92% and specificity of 95% compared with the MAT (54292.6(wit.8(studiTv582.6(MAT)-2iTv592.6()-2iTv592.6and)niTv592y92.fand)r

s-445.4aonsaggl7 0 0 5.5 311590.75 Tmn32

quences were the least specific, and none of the methods was 100% sensitive. A combination of two detection methods chosen from PCR, immunofluorescence, and culture was the most sensitive.

A limitation of PCR-based diagnosis of leptospirosis is the inability of most PCR assays to identify the infecting serovar. While this is not significant for individual patient management, the identity of the serovar has significant epidemiological and public health value. Strategies designed to overcome this obstacle have included restriction endonuclease digestion of PCR products (85, 502), direct sequencing of amplicons (424), and single-strand conformation analysis (SSCP) (380, 647). Leptospiral genomospecies but not individual serovars can be differentiated following PCR by electrophoresis in nondenaturing polyacrylamide gels, followed by silver staining (424), without eruc537PCR6e((SSCP_PCR327.537PCRRFLP7.537PCRin28537PCR)-27typi7.537PCRhardjobovisne537PCRisololll28537PCRveratedern

primers is their use under low-stringency conditions, generating a mixture of specific and nonspecific products (150). Under these conditions, the G1 and G2 primers amplify all species, including *L. interrogans*. Polymorphisms were detected which allowed discrimination of serovars with the exception of closely related serovars, including copenhageni and icterohaemorrhagiae (85, 150).

The presence of multiple copy insertion sequences has been exploited for serovar identification (481, 502, 670, 671). Methods based on *IS1533* have limited application because of the absence of this insertion sequence in *L. interrogans sensu stricto* and *L. interrogans sensu lato* (481, 670). By amplifying the sequences between adjacent copies of *IS1500*, numerous genetic subgroups within serovar pomona type kennewickii were distinguished (671).

RFLP analysis of PCR-amplified 16S and 23S rRNA genes allowed the grouping of 48 serovars into 16 mapped restriction site polymorphism profiles (469). Using this approach, the genospecies of *L. interrogans* could be identified, and the genotypes hardjobovis and hardjoprajtino of serovar hardjo were clearly distinguished (453). The method was simplified to yield only five profiles by using a single restriction enzyme (638). One of the potential advantages of this RFLP approach is the ability to amplify leptospiral DNA from clinical material and to identify the infecting serovar or genospecies rapidly in the absence of an isolate. Other workers have used primers that amplify only a restricted range of serovars (85, 502), limiting the utility of the approach unless several primer sets are used (85).

DNA fingerprinting using arbitrary primers (625, 629) has been studied extensively (85, 128, 129, 237, 453, 469), using different primers and conditions. Direct comparison between the results of these studies is therefore impossible, but it is clear that reproducibility is difficult to achieve without absolute standardization of experimental procedure. Profiles are affected markedly by the primer used, the quantity and quality of the DNA template (128, 380, 599), and the electrophoresis conditions (129). The greatest value of arbitrary primer techniques lies in their ability to differentiate between isolates when the range of potential serovars is limited, allowing rapid identification of freshly isolated strains (85, 128, 237). Arbitrary-primed PCR was used to derive species-specific probes for identification of *L. interrogans sensu stricto*, *L. interrogans sensu lato*, and *L. interrogans sensu lato* by dot blotting (347). A cluster of 43 *L. interrogans sensu stricto* isolates from a number of Brazilian outbreaks were shown to have identical arbitrary-primed PCR fingerprints (449) despite the inclusion of isolates of serovars copenhageni and canicola.

The etiology and epidemiology of leptospirosis have been understood for many years, and this knowledge has led to the development of effective preventive strategies. In developed countries, leptospirosis continues to be a disease of considerable economic significance in animal husbandry, but the major burden of human disease remains in tropical and subtropical developing countries. Several recent outbreaks of leptospirosis have drawn attention to the potential effects of climate change and human activity on the incidence of the disease and the

broad spectrum of clinical manifestations. The development of several promising approaches to rapid diagnosis has been based largely on the recognition that early initiation of antibiotic therapy is important in acute disease, but also on the need for simpler assays which can be used more widely. However, many of these diagnostic advances will be unavailable to those populations for which they would be most useful. At a more fundamental level, understanding of the mechanisms of pathogenesis remains incomplete, but recent advances in the molecular biology of leptospires offer the prospect of more rapid progress in the future.

I thank the many colleagues who have assisted me with access to the literature, particularly Esther Maria Fajardo, Peter Gaskin, Albert Ko, Diane Van Alstyne, and Rob Weyant and the staff of the Information Center, CDC, Atlanta, Ga.

1. Vascular injury in acute renal failure due to leptospirosis is not associated with antineutrophil cytoplasmic antibody. *Nephron*. 1993; 156.
2. Acute renal failure in leptospirosis. *Renal Failure*. 191-198.
3. Inhibition of leptospiral agglutination

20. 1972. Preservation of leptospiras by liquid-nitrogen refrigeration. *Int. J. Syst. Bacteriol.* . 165-169.
21. 1986. Penicillins, cephalosporins, and tetracyclines in treatment of hamsters with fatal leptospirosis. *Antimicrob. Agents Chemother.* 0 835-839.
22. 1989. Massive pulmonary haemorrhage due to leptospirosis. *Intensive Care Med.* 1 . 322-324.
23. 1935. Leptospiral jaundice among sewer-workers. *Lancet* . 806-809.
24. 1958. *Leptospirosis in man and animals.* E. & S. Livingstone, Edinburgh, U.K.
25. 0.

- between serogroups and serovars in the family *L* with a proposal for *L* sp. nov. and four new *L* genospecies. *Int. J. Syst. Bacteriol.* 38: 839–858.
- 82.▲ . 1985. Prevention of renal carriage of leptospirosis in dogs by vaccination. *Vet. Rec.* 11: 307–311.
- 83.▲ . 1996. *L* serovar infection in dogs. *J. Am. Vet. Med. Assoc.* 10: 1265–1267.
- 84.▲ . 1995. Evaluation of the polymerase chain reaction for early diagnosis of leptospirosis. *J. Med. Microbiol.* 42: 110–114.
- 85.▲ . 1997. Differentiation of *L* species and serovars by PCR-restriction endonuclease analysis, arbitrarily primed PCR and low-stringency PCR. *J. Med. Microbiol.* 44: 173–181.
- 86.▲ . 1927. Spirochaetal jaundice. Special Report Series, no. 113. Medical Research Council, London, U.K.
- 87.▲ . 1945. Mud fever (leptospirosis) in the British army in France. *Lancet* 1: 331–333.
- 88.▲ . 2000. Functional analysis of genes in the *locus* of *L* serovar hardjo subtype hardjobovis. *Infect. Immun.* 68: 3793–3798.
- 89.▲ . 1976. Leptospirosis presenting with profuse haemoptysis. *BMJ* 3: 982.
- 90.▲ . 1997. Purification and characterization of a Na⁺/K⁺ ATPase inhibitor found in an endotoxin of *L*. *Infect. Immun.* 65: 157–1560.
- 91.▲ . 2000. Leptospirosis complicated by severe aortic stenosis. *Anaesth. Intensive Care* 48: 434–437.
- 92.▲ . 1987. A waterborne outbreak of leptospirosis. *Am. J. Epidemiol.* 125: 533–545.
- 93.▲ . 1977. Brote de leptospirosis en niños de Longhamps, Pcia de Buenos Aires, Argentina: daignostico de laboratorio. *Rev. Argent. Microbiol.* 9: 126–128.
- 94.▲ . 1995. ELISA-IgM applied to cerebrospinal fluid in human leptospirosis. *Serodiagn. Immunother. Infect. Dis.* 1: 19–22.
- 95.▲ . 2000. Analysis of the 1998 outbreak of leptospirosis in Missouri in humans exposed to infected swine. *J. Am. Vet. Med. Assoc.* 197: 676–682.
- 96.▲ . 1947. The value of spinal fluid examination as a diagnostic procedure in Weil's disease. *Ann. Intern. Med.* 3: 396–400.
- 97.▲ . 1997. Case definitions for infectious conditions under public health surveillance. *Morb. Mortal. Wkly. Rep.* (RR-10) 49.
- 98.▲ . 1998. Outbreak of acute febrile illness among athletes participating in triathlons—Wisconsin and Illinois, 1998. *Morb. Mortal. Wkly. Rep.* 47: 585–588.
- 99.▲ . 2000. Outbreak of acute febrile illness among participants in EcoChallenge Sabah 2000—Malaysia, 2000. *Morb. Mortal. Wkly. Rep.* 49: 816–817.
- 100.▲ . 1995. Outbreak of acute febrile illness and pulmonary hemorrhage—Nicaragua, 1995. *Morb. Mortal. Wkly. Rep.* 44: 841–843.
- 101.▲ . 1994. Summary of notifiable diseases, United States 1994. *Morb. Mortal. Wkly. Rep.* (53) 1–80.
- 102.▲ . 1998. Update: leptospirosis and unexplained acute febrile illness among athletes participating in triathlons—Illinois and Wisconsin, 1998. *Morb. Mortal. Wkly. Rep.* 47: 673–676.
- 103.▲ . 1991. Detection and characterization of leptospiral antigens using a biotin/avidin double-antibody sandwich enzyme-linked immunosorbent assay and immunoblot. *Can. J. Vet. Res.* 52: 239–245.
- 104.▲ . 1987. Leptospirosis among abattoir workers—a serological study. *Singapore Med. J.* 88: 293–296.
- 105.▲ . 1937. The use of erythrocyte sensitizing substance in the diagnosis of leptospiroses. II. The sensitized erythrocyte lysis test. *Am. J. Trop. Med. Hyg.* 1: 101–107.
- 106.▲ . 1948. Studies on *L*. IV. Survival in water and sewage: destruction in water by halogen compounds, synthetic detergents, and heat. *J. Infect. Dis.* 63: 256–266.
- 107.▲ . 1988. Antigens recognised by the human immune response to infection with *L* serovar . *J. Med. Microbiol.* 26: 269–278.
- 108.▲ . 1987. Genus-specific antigens in *Leptospira* revealed by immunoblotting. *Zentbl. Bakteriol.* 186: 279–283.
- 109.▲ . 1984/85. Enzymatic radioimmunoassay for detecting serovar in the urine of experimentally-infected pigs. *Vet. Microbiol.* 10: 279–286.
- 110.▲ . 1985. Adult respiratory distress syndrome in *L* infection. *Intensive Care Med.* 11: 254–256.
- 111.▲ . 1985. Development and present status of leptospiral vaccine and technology of vaccine production in China. *Jpn. J. Bacteriol.* 40: 755–762.
- 112.▲ . 1976. The dynamics of IgM- and IgG-antibodies in leptospiral infection in man. *Zentbl. Bakteriol.* 175: 336–343.
- 113.▲ . 1982. Immunogenicity of leptospiral vaccines grown in protein-free medium. *J. Med. Microbiol.* 1: 493–501.
- 114.▲ . 1998. Identification of *L* species in the pathogenesis of uveitis and determination of clinical ocular characteristics in South India. *J. Infect. Dis.* 177: 1314–1321.
- 115.▲ . 1958. Leptospirosis. A clinical and statistical study of 182 cases. *Chin. Med. J.* 23: 207–235.
- 116.▲ . 1963. Transplacental or congenital infection of leptospirosis. *Chin. Med. J.* 28: 777–782.
- 117.▲ . 1983. Interactions between human polymorphonuclear leukocytes and one strain of pathogenic *L* (*L.* sp.) and one of saprophytic *L* (*L.* sp.). *FEMS Microbiol. Lett.* 1: 51–54.
- 118.▲ . 1981. Studies on the interaction between macrophages and leptospines. *J. Gen. Microbiol.* 121: 409–413.
- 119.▲ . 1980. Cytotoxic activity of supernatant extracts of virulent and saprophytic leptospines. *Zentbl. Bakteriol.* 179: 260–267.
- 120.▲ . 1954. Human leptospirosis associated with a swimming pool, diagnosed after eleven years. *Am. J. Hyg.* 60: 1–7.
- 121.▲ . 1962. Leptospirosis due to *L*. An outbreak of nine cases. *JAMA* 191: 1077–1078.
- 122.▲ . 1969. Leptospirosis in human pregnancy followed by death of the foetus. *BMJ* 1: 228–230.
- 123.▲ . 1982. Infections with *E* and *L* serovars and in a kennel of foxhounds. *J. Am. Vet. Med. Assoc.* 181: 435–437.
- 124.▲ . 1973. Improved microtechnique for the leptospiral microscopic agglutination test. *Appl. Microbiol.* 26: 976–980.
- 125.▲ . 1991. Plasmid analysis of *L*, p. 462–473. Y. Kobayashi (ed.), *Leptospirosis. Proceedings of the Leptospirosis Research Conference 1990*. University of Tokyo Press, Tokyo, Japan.
- 126.▲ . 2000. Leptospirosis outbreak in EcoChallenge 2000 participants. *Commun. Dis. Rep.* 10: 341.
- 127.▲ . 1996. Antineutrophil cytoplasmic antibodies in leptospirosis. *J. Rheumatol.* 23: 411.
- 128.▲ . 1993. Rapid identification of some *L* isolates from cattle by random amplified polymorphic DNA fingerprinting. *J. Clin. Microbiol.* 31: 2927–2932.
- 129.▲ . 1997. Simplified analysis of pathogenic leptospiral serovars by random amplified polymorphic DNA fingerprinting. *J. Med. Microbiol.* 44: 927–932.
- 130.▲ . 1990. A waterborne outbreak of leptospirosis among United States military personnel in Okinawa, Japan. *Int. J. Epidemiol.* 19: 743–748.
- 131.▲ . 1916. Un cas de spirochétose ictéro-hémorragique. *Bull. Mém. Soc. Méd. Hôpitaux de Paris* 40: 1635–1639.
- 132.▲ . 1936. Weil's disease in North Queensland. *BMJ* 1: 51–56.
- 133.▲ . 2000. Massive rhabdomyolysis

- hemolytic test in the serodiagnosis of human leptospirosis. *J. Infect. Dis.* **101**:210-218.
137. . 1971. Human infections associated with waterborne leptospires, and survival studies on serotype . *J. Am. Vet. Med. Assoc.* **1**:1477-1484.
138. . 1980. *L* associated with an outbreak of illness in workers on a farm in North Yorkshire. *Br. J. Ind. Med.* **37**:397-398.
139. . 1991. Further evaluation of one-point microcapsule agglutination test for diagnosis of leptospirosis. *Epidemiol. Infect.* **10**:561-565.
140. . 1999. Assessment of the efficacy of the IgM enzyme-linked immunosorbent assay (ELISA) and microscopic agglutination test (MAT) in the diagnosis of acute leptospirosis. *Am. J. Trop. Med. Hyg.* **1**:731-734.
141. . 1999. Risk factors for death and changing patterns in leptospirosis acute renal failure. *Am. J. Trop. Med. Hyg.* **1**:630-634.
142. . 1994. Identification of pathogenic leptospires by recombinant DNA probes. *Chin. Med. Sci. J.* **29**:209-214.
143. . 1990. Leptospirosis in patients with anti-HIV antibodies: report of 2 cases. *Rev. Soc. Bras. Med. Trop.* **23**:229-231.
144. . 1989. Is thrombocytopenia seen in patients with leptospirosis immunologically mediated? *J. Clin. Pathol.* **42**:439-440.
145. . 1916. Jaundice of infective origin. *Q. J. Med.* **10**:90-131.
146. . 1987. Fatal leptospiral myocarditis. *G. Ital. Cardiol.* **1**:992-994.
147. . 1965. Electron microscopy of the biopsied kidney in human leptospirosis. *Am. J. Trop. Med. Hyg.* **1**:397-403.
148. . 1967. Liver biopsy in human leptospirosis: a light and electron microscopy study. *Virchows Arch. Pathol. Anat.* **36**:61-69.
149. . 1987. Cardiovascular involvement in human and experimental leptospirosis: pathologic findings and immunohistochemical detection of leptospiral antigen. *Ann. Trop. Med. Parasitol.* **1**:207-214.
150. . 1994. Low-stringency PCR with diagnostically useful primers for identification of *L*

252. 2000. Antibiotics for treating leptospirosis (Cochrane Review). Cochrane Library, Issue 2. Update Software, Oxford, U.K.

253. 1997. LEPTO dipstick, a dipstick assay for detection of *L.*-specific immunoglobulin M antibodies in human sera. *J. Clin. Microbiol.* . . 92-97.

254. 2000. Spirochaetal lipoproteins and pathogenesis. *Microbiology* . . 1491-1504.

255. 1993. Molecular cloning and sequence analysis of the gene encoding OmpL1, a transmembrane outer membrane protein of pathogenic *L.* spp. *J. Bacteriol.* . . 4225-4234.

256. 2000. The leptospiral major outer membrane protein LipL32 is a lipoprotein expressed during mammalian infection. *Infect. Immun.* . . 2276-2285.

257. 1998. Characterization of leptospiral outer membrane lipoprotein LipL36: downregulation associated with late-log-phase growth and mammalian infection. *Infect. Immun.* . . 1579-1587.

258. 1999. Leptospiral outer membrane proteins OmpL1 and LipL41 exhibit synergistic immunoprotection. *Infect. Immun.* . . 6572-6582.

259. 1991. Changes in the surface of *L.* serovar grippityphosa during in vitro cultivation. *Infect. Immun.* . . 1131-1140.

260. 1969. De-

oe.14255.3 rf-3255.3 the(l255.3 Pomonp. 255.3 [(ggrou. 255.3 islea2[(99.)022.8(during

308. | *Leptospira interrogans* sensu stricto. J. 1937. Weil's disease in
Brisbane. Med. J. Aust. 1: 811-818.
309. | *Leptospira interrogans* sensu stricto. 1984. *L. interrogans*, p. 62-67. In: N. R. Krieg and
J. G. Holt (ed.), Bergey's manual of systematic bacteriology, vol. 1. Williams
& Wilkins, Baltimore, Md.
310. | *Leptospira interrogans* sensu stricto. 1967. Differentiation of pathogenic and
saprophytic leptospirae. 1. Growth at low temperatures. J. Bacteriol. 88: 27-
31.
311. | *Leptospira interrogans* sensu stricto. 1964. 5-Fluorouracil as a selective agent for
growth of leptospirae. J. Bacteriol. 88: 422-426.
312. | *Leptospira interrogans* sensu stricto. 1973. Cultivation
of parasitic leptospirae: effect of pyruvate. Appl. Microbiol. 26: 118-119.
- 313.

organisms. *J. Clin. Microbiol.*

422. 1998. Leptospirosis and acute pancreatitis: a report of ten cases. *Pediatr. Infect. Dis. J.* 17: 436-438.
423. 1983. In vitro susceptibilities of five *L.* strains to 16 antimicrobial agents. *Antimicrob. Agents Chemother.* 17: 905-908.
424. 1995. Use of nondenaturing silver-stained polyacrylamide gel analysis of polymerase chain reaction amplification products for the differential diagnosis of *L.* infection. *Diagn. Microbiol. Infect. Dis.* 11: 343-348.
425. 1977. Observations on a new epidemic outbreak of leptospirosis in greater Recife, Brazil, in 1975. *Rev. Inst. Adolfo Lutz* 33: 33-36.
426. 1991. Pulmonary manifestations of leptospirosis. *Rev. Infect. Dis.* 13: 705-709.
427. 1979. Isolation of leptospira of the serotype from bovine kidneys. *Res. Vet. Sci.* 30: 343-346.
428. 1993. The search for improved methods for diagnosing leptospirosis: the approach of a laboratory in Brescia, Italy. *Rev. Sci. Tech.* 12: 647-663.
429. 1992. Repetitive sequences cloned from *L.* serovar

- leptospirosis. *Am. J. Ophthalmol.* **1** : 71-79.
478. . 1996. Leptospiral antibodies in patients with recurrent ophthalmic involvement. *Indian J. Med. Res.* **10** : 66-68.
479. . 1994. Leptospirosis: an Indian perspective. *Indian J. Med. Microbiol.* **1** : 228-239.
480. . 1984. Humoral and cell-mediated immune responses to leptospire in different human cases. *Trans. R. Soc. Trop. Med. Hyg.* **1** : 539-542.
481. . 1996. The development of a ligase mediated PCR with potential for differentiation of serovars within *L* . . *Vet. Microbiol.* **1** : 351-362.
482. . 1997. Outbreak of leptospirosis among white-water rafters—Costa Rica, 1996. *Morb. Mortal. Wkly. Rep.* **1** : 577-579.
483. . 2000. *B* gene analysis as a novel strategy for identification of spirchetes from the genera *B* , *T* , and *L* . *J. Clin. Microbiol.* **1** : 2200-2203.
484. . 1994. Serodiagnosis of human leptospirosis employing immunodominant antigen. *Serodiagn. Immunother. Infect. Dis.* **1** : 140-144.
485. . 1995. Dot-ELISA for human leptospirosis employing immunodominant antigen. *J. Trop. Med. Hyg.* **1** : 452-456.
486. . 1990. Cloning of genes required for amino acid biosynthesis from *L* serovar . . *J. Gen. Microbiol.* **1** : 651-656.
487. . 1958. Simple method for separating leptospirae from contaminating microorganisms. *J. Bacteriol.* **1** : 669-670.
488. . 1963. Comparison of the complement-fixation test and the microscopic agglutination test (agglutination-lysis) for the detection of leptospiral serogroup antibodies. *Can. J. Comp. Med.* **1** : 113-120.
489. . 1981. Leptospirosis in trout farmers. *Lancet* **1** : 626-627.
490. . 1982. Differentiation of subtypes within *L* serovars and by bacterial restriction-endonuclease DNA analysis (BRENDA). *J. Med. Microbiol.* **1** : 331-338.
491. . 1976. The agglutinating and immunofluorescent activities of antileptospiral antibodies of human sera and of immunoglobulins M and G. *J. Hyg. Epidemiol. Microbiol. Immunol.* **0** : 341-352.
492. . 1998. Detection of *L* DNA in patients with aseptic meningitis by PCR. *J. Clin. Microbiol.* **1** : 1453-1455.
493. . 1998. The persistence of leptospiral agglutinins titers in human sera diagnosed by the microscopic agglutination test. *Rev. Inst. Med. Trop. Sao Paulo* **0** : 183-184.
494. . 1961. The use of agar plates as an aid for the isolation of leptospire. *Am. J. Vet. Res.* **1** : 308-312.
495. . 1991. Anticardiolipin antibodies in leptospirosis. *J. Clin. Pathol.* **1** : 517-519.
496. . 1986. Gellan gum as a substitute for agar in leptospiral media. *J. Clin. Microbiol.* **1** : 500-504.
497. . 1958. Treatment of leptospirosis with oxytetracycline. *Lancet* **1** : 1143-1145.
498. . 2000. The LE1 bacteriophage replicates as a plasmid within *L* : construction of an *L* -*E* shuttle vector. *J. Bacteriol.* **1** : 5700-5705.
499. . 1985. Detection of antibodies to leptospiral genus-specific antigen in human and animal sera by indirect hemagglutination test with a partially purified genus-specific protein antigen. *Zentbl. Bakteriol.* **1** : 548-556.
500. . 1969. Benign leptospirosis: first reported outbreak in the British Isles due to strains belonging to the Hebdomadis serogroup of *L* . *BMJ* **1** : 226-228.
501. . 1999. Increase of leptospirosis in dengue-negative patients after a hurricane in Puerto Rico in 1996. *Am. J. Trop. Med. Hyg.* **1** : 399-404.
502. . 1994. Detection and identification of *L* serovars by PCR coupled with restriction endonuclease analysis of amplified DNA. *J. Clin. Microbiol.* **1** : 935-941.
503. . 1951. Leptospiral meningitis. Investigation of a water-borne epidemic due to *L* . *J. Clin. Investig.* **0** : 670-671.

H. A. Lechavelier (ed.), CRC handbook of microbiology, 2nd ed, vol. 1. CRC Press, Cleveland, Ohio.

531. *L. interrogans* serovar *icola*. 1955. Observations on the survival of *L. interrogans* serovar *icola* in soil and water. *J. Hyg.* 75:436-444.
532. *L. interrogans* serovar *icola*. 1949. Weil's disease in the north-east of Scotland. *Br. J. Ind. Med.* 4:213-220.
533. *L. interrogans* serovar *icola*. 1999. International multicenter evaluation of the clinical utility of a dipstick assay for detection of *L. interrogans*-specific immunoglobulin M antibodies in human serum specimens. *J. Clin. Microbiol.* 37:2904-2909.
534. *L. interrogans* serovar *icola*. 2000. Simple latex agglutination assay for rapid serodiagnosis of human leptospirosis. *J. Clin. Microbiol.* 38:1272-1275.
535. *L. interrogans* serovar *icola*. 2000. Review of leptospirosis notifications in Queensland and Australia: January 1998-June 1999. *Commun. Dis. Intell.* 24:153-157.
536. *L. interrogans* serovar *icola*. 1951. The cardiac manifestations of Weil's disease. *Am. J. Trop. Med. Hyg.* 10:479-488.
537. *L. interrogans* serovar *icola*. 1987. Rhabdomyolysis in leptospirosis (Weil's disease). *J. Infect. Dis.* 155:692-693.
538. *L. interrogans* serovar *icola*. 2000. Evidence of cross-protection within *L. interrogans* in an experimental model. *Vaccine* 18:86-94.
539. *L. interrogans* serovar *icola*. 1979. Plate assay for detection of *L. interrogans* serovar *icola* hemolysin. *J. Clin. Microbiol.* 10:590-592.
540. *L. interrogans* serovar *icola*. 1991. Cloning of the *recA* gene from a free-living leptospire and distribution of RecA-like protein among spirochetes. *Appl. Environ. Microbiol.* 57:183-189.
541. *L. interrogans* serovar *icola*. 1973. Growth requirements of pathogenic *L. interrogans*. *Infect. Immun.* 9:886-897.
542. *L. interrogans* serovar *icola*. 1907. Note on an organism found in yellow-fever tissue. *Public Health Rep.* 22:541.
- 542a. *L. interrogans* serovar *icola*. 2000. Leptospirosis occurring in two children after fresh water immersion. *West Indian Med. J.* 49:340-343.
543. *L. interrogans* serovar *icola*. 1917. Weil's disease (Spirochaetosis ictero-haemorrhagica) in the British army in Flanders. *Lancet* 1:142-153.
544. *L. interrogans* serovar *icola*. 1959. Weil's disease associated with pancreatic necrosis. *Trop. Geogr. Med.* 11:93-95.
545. *L. interrogans* serovar *icola*. 1939. Weil's disease in Glasgow sewer workers. *BMJ* 1:324-326.
546. *L. interrogans* serovar *icola*. 1975. Evaluation of an indirect hemagglutination test for the diagnosis of human leptospirosis. *J. Clin. Microbiol.* 13:218-221.
547. *L. interrogans* serovar *icola*. 1973. Evaluation of a hemagglutination test for human leptospirosis. *Appl. Microbiol.* 26:655-657.
548. *L. interrogans* serovar *icola*. 1978. Leptospirosis: methods in laboratory diagnosis. U.S. Department of Health, Education and Welfare, Atlanta, Ga.
549. *L. interrogans* serovar *icola*. 1973. A modivoox6ee.1526 TD(Ga.)Tj-2.29Hs7 Bh(1978.p235.8(dis8.p235.8(79.6(humanee18(M75 0 TD[(divoo32.8(leptospi6(diag.3272 rosis.)

585. . . . 1967. Leptospirosis I. Trans. R. Soc. Trop. Med. Hyg. . 1. 842-855.
586. . . . 1968. Leptospirosis II. Serology. Trans. R. Soc. Trop. Med. Hyg. . 880-889.
- 586a. . . . 1969. Leptospirosis. . 231-235.
587. . . . 1970. Leptospirosis III. Maintenance, isolation and demonstration of leptospire. Trans. R. Soc. Trop. Med. Hyg. . 623-646.
588. . . . 1915. Experimentelle Untersuchungen über die sogenannte Weilsche Krankheit (ansteckende Gelbsucht). Med. Klin. . 1202-1203.
589. . . . 1992. Diagnóstico precoce da leptospirose por demonstração de antígenos através de exame imuno-histoquímico em músculo da panturrilha. Rev. Inst. Med. Trop. Sao Paulo . 375-381.
590. . . . 2000. Descripción de un brote de leptospirosis en la ciudad de Santa Fe, Argentina, marzo-abril de 1998. Rev. Panam. Salud Pública . 35-40.
591. . . . 1994. Leptospirosis in travelers. Clin. Infect. Dis. 1 . 132-134.
592. . . . 1984. Platelet autoantibodies in septicæmia. Br. J. Haematol. . 755-760.
593. . . . 1991. Characterization of serovars of the genus *L.*

- genus *Leptospira*. *Vet. Microbiol.* 10: 239-251.
641. . 1991. Nucleotide sequence of a repetitive element isolated from *L. interrogans* serovar type . *J. Gen. Microbiol.* 137: 1101-1109.
642. . 1997. *L. interrogans* serodiagnosis: a comparison of MAT, ELISA and immunocomb. *Vet. Rec.* 140: 603-604.
643. . 1991. Development of a PCR test specific for *L. interrogans* genotype . *Vet. Rec.* 128: 282-283.
644. . 1953. The protean manifestations of leptospirosis, p. 57-68. *I Symposium on the leptospiroses*. U.S. Government Printing Office, Washington, D.C.
645. . 2000. Leptospirosis, India: report of the investigation of a post-cyclone outbreak in Orissa, November 1999. *Wkly. Epidemiol. Rec. WHO* 25: 217-223.
646. . 1999. Leptospirosis worldwide, 1999. *Wkly. Epidemiol. Rec.* 24: 237-242.
647. . 1996. 16S rRNA gene PCR-SSCP analysis of the reference strains from 15 serovars (14 serogroups) of pathogenic leptospires in China. *Hua Hsi I Ko Ta Hsueh Hsueh Pao* 17: 17-20.
648. . 1947. The sensitivity of organisms of the genus *Leptospira* to penicillin and streptomycin. *J. Pathol. Bacteriol.* 50: 247-254.
649. . 1990. The study on genome size of leptospires. *Hua Hsi I Ko Ta Hsueh Pao* 11: 362-365.
650. . 1980. Moyamoya disease caused by leptospiral cerebral arteritis. *Chin. Med. J.* 5: 599-604.
651. . 1970. A leptospiral factor producing a cytopathic effect on L cells. *J. Infect. Dis.* 122: 310-317.
652. . 1991. Cellular immune response analysis of patients with leptospirosis. *Am. J. Trop. Med. Hyg.* 44: 138-145.
653. . 1999. Development of an ELISA to detect antibodies to a protective lipopolysaccharide fraction of *Leptospira borgpetersenii* serovar hardjo in cattle. *Vet. Microbiol.* 65: 173-187.
654. . 1998. Development of an immunomagnetic antigen capture system for detecting leptospires in bovine urine. *Res. Vet. Sci.* 79: 119-124.
655. . 1982. Hemolytic activity of *L. interrogans* serovar cultured in protein-free medium. *Microbiol. Immunol.* 25: 547-556.
656. . 1986. Experimental leptospirosis (*L. interrogans* serovar icterohaemorrhagiae) of the guinea pig: leptospiral antigen, gamma globulin and complement C3 detection in the kidney. *Exp. Pathol.* 15: 35-43.
657. . 1991. Evaluation of counterimmunoelectrophoresis with antigens of and serovars in the serodiagnosis of human leptospirosis. *Rev. Inst. Med. Trop. Sao Paulo* 33: 497-502.
658. . 1987. Deoxyribonucleic acid relatedness between serogroups and serovars in the family *L.* with proposals for seven new *L.* species. *Int. J. Syst. Bacteriol.* 37: 407-415.
659. . 2000. Pulmonary haemorrhage as a predominant cause of death in leptospirosis in Seychelles. *Trans. R. Soc. Trop. Med. Hyg.* 74: 71-76.
660. . 1998. Human leptospirosis in the Seychelles (Indian Ocean): a population-based study. *Am. J. Trop. Med. Hyg.* 58: 933-940.
661. . 1999. Field evaluation of a one-step dipstick assay for the diagnosis of human leptospirosis in the Seychelles. *Trop. Med. Int. Health* 4: 38-45.
662. . 1995. Inhibition of Na,K-ATPase by an endotoxin extracted from *L. interrogans*: a possible mechanism for the physiopathology of leptospirosis. *C. R. Acad. Sci. III* 304: 619-625.
663. . 1999. Chemotaxis of leptospires to hemoglobin in relation to H8(Hyg.)TJ/F99.6